

УДК: 616.36-002.272-053.2-089.87

## OUTCOMES OF LAPAROSCOPIC ECHINOCOCCECTOMY IN PEDIATRIC PATIENTS WITH COMPLICATED LIVER ECHINOCOCCOSIS: EXPERIENCE FROM A SINGLE CENTER

Elmuradov Sh.Kh.<sup>1</sup>, Usmanov Kh.S.<sup>2</sup>, Abdusamatov B.Z.<sup>2</sup>, Salimov Sh.T.<sup>2</sup>,  
Berdiev E.A.<sup>1</sup>, Ergashev M.R.<sup>1</sup>, Suvonkulov U.T.<sup>3</sup>

<sup>1</sup>Republican Scientific and Practical Center for Minimally Invasive and Endoscopic Surgery  
of Children, Tashkent, Uzbekistan

<sup>2</sup>Tashkent Medical Academy, Uzbekistan

<sup>3</sup>Samarkand Medical University, Uzbekistan

## РЕЗУЛЬТАТЫ ЛАПАРОСКОПИЧЕСКОЙ ЭХИНОКОККЭКТОМИИ У ДЕТЕЙ С ОСЛОЖНЕННЫМ ЭХИНОКОККОЗОМ ПЕЧЕНИ: ОПЫТ ОДНОГО ЦЕНТРА

Ш.Х. Элмуратов<sup>1</sup>, Х.С. Усманов<sup>2</sup>, Б.З. Абдусаматов<sup>2</sup>, Ш.Т. Салимов<sup>2</sup>,  
Э.А. Бердиев<sup>1,2</sup>, М.Р. Эргашев<sup>1</sup>, У.Т. Сувонкулов<sup>3</sup>

<sup>1</sup>Республиканский научно-практический центр малоинвазивной и эндоскопической хирургии детского  
возраста, Ташкент, Узбекистан

<sup>2</sup>Ташкентская медицинская академия, Узбекистан

<sup>3</sup>Самаркандский медицинский университет, Узбекистан

**Summary.** This study examines the outcomes of laparoscopic echinococcectomy for complicated liver echinococcosis, performed at the Republican Scientific and Practical Center of Minimally Invasive and Endoscopic Surgery of Childhood (RSPCMIESC). A total of 72 pediatric patients, aged 6–18 years, underwent the procedure. Suppurative echinococcal cysts (ECs) represented the most frequent complication, observed in 38 patients (52.8%), followed by cyst ruptures into the bile ducts in 14 cases (19.4%). Additionally, perforation of cyst contents into the free abdominal cavity occurred in 16 patients (22.2%), and calcified ECs were identified in 4 cases (5.6%).

In 81.9% (n=59) of the cases, laparoscopic echinococcectomy was successfully completed, while 13 patients (18.1%) required conversion to laparotomy and conventional echinococcectomy due to technical challenges. Based on these findings, the authors conclude that complicated and multiple ECs of the liver (up to 4 cysts) represent a relative contraindication for laparoscopic echinococcectomy.

**Key words:** *Echinococcus; complication; children; laparoscopic echinococcectomy.*

**Резюме.** В данной работе рассматриваются результаты лапароскопической эхинококкэктомии при осложненном эхинококкозе печени, выполненной в Республиканском научно-практическом центре малоинвазивной и эндоскопической хирургии детского возраста (РНПЦ МиЭХДВ). Всего было 72 ребенка в возрасте от 6 до 18 лет. Наиболее частым осложнением были нагноившиеся эхинококковые кисты (ЭК), отмеченные у 38 (52,8%) пациентов, за которыми следовали прорыв кист в желчные протоки в 14 (19,4%) случаях. Кроме того, у 16 (22,2%) пациентов наблюдалась перфорация содержимого кист в брюшную полость, а в 4 (5,6%) случаях были выявлены кальцинированные ЭК. В 81,9% (n=59) случаев лапароскопическая эхинококкэктомия была успешно завершена, в то время как 13 (18,1%) пациентам потребовалась конверсия на лапаротомию и традиционную эхинококкэктомию из-за технических трудностей. На основании этих данных авторы делают вывод, что сложные и множественные ЭК печени (до 4 кист) являются относительным противопоказанием для лапароскопической эхинококкэктомии.

**Ключевые слова:** *эхинококк, осложнение, дети, лапароскопическая эхинококкэктомия.*

**Для цитирования:** Абдусаматов Б.З., Салимов Ш.Т., Элмуратов Ш.Х., Усманов Х.С., Бердиев Э.А., Эргашев М.Р., Сувонкулов У.Т. РЕЗУЛЬТАТЫ ЛАПАРОСКОПИЧЕСКОЙ ЭХИНОКОККЭКТОМИИ У ДЕТЕЙ С ОСЛОЖНЕННЫМ ЭХИНОКОККОЗОМ ПЕЧЕНИ: ОПЫТ ОДНОГО ЦЕНТРА. INNOVATIVE SURGERY ON THE SILK ROAD. 2024; 2(2):51-58.

**For citation:** Abdusamatov B.Z., Salimov Sh.T., Elmuradov Sh.Kh., Usmanov Kh.S., Berdiev E.A., Ergashev M.R., Suvonkulov U.T. OUTCOMES OF LAPAROSCOPIC ECHINOCOCCECTOMY IN PEDIATRIC PATIENTS WITH COMPLICATED LIVER ECHINOCOCCOSIS: EXPERIENCE FROM A SINGLE CENTER. INNOVATIVE SURGERY ON THE SILK ROAD. 2024; 2(2):51-58.

**Introduction.** Despite advancements in the treatment and prevention of liver echinococcosis, there has been a noticeable rise in the incidence of the disease in recent years. Many challenges remain unresolved, particularly in determining optimal surgical strategies for managing this condition [1-3]. Complicated forms of liver echinococcosis have consistently drawn the attention of researchers, as these cases often present with the most pronounced clinical symptoms. Patients at this stage of the disease constitute the majority of those hospitalized for treatment [4, 5].

The integration of modern, highly sensitive imaging techniques such as ultrasound, computed tomography (CT), and magnetic resonance imaging (MRI) into clinical practice has significantly enhanced the early detection of liver echinococcosis and its complications [6]. Nonetheless, improving the diagnostic accuracy for complicated cases remains a pressing concern [7, 8]. Even after comprehensive imaging evaluations, the correct diagnosis is achieved in only 46% of cases. Moreover, 37–86% of patients are admitted to the hospital when clinical complications of the parasitic disease have already developed [9, 10].

Currently, surgical intervention remains the primary treatment for complicated liver echinococcosis, with limited alternatives in the majority of cases. However, surgery entails significant risks due to factors such as the patient's condition, the location of parasitic lesions, and the number of previous surgeries. Outcomes are often impacted by complications arising from residual cavities (RC) left after cyst removal, including suppuration, bleeding, and the formation of external bile or purulent fistulas. Surgical management aims to achieve either radical removal of echinococcal cysts (ECs) through liver resection or echinococcectomy supplemented by measures to prevent recurrence [11, 12].

Despite these advancements, there is a growing need to explore and develop minimally invasive surgical techniques. Some researchers (Shangareeva R.Kh., 2010; Gumerov A.A., 2012) argue that large and multiple (>2) complicated perforated ECs, as well as subdiaphragmatic localization (segments VII–VIII), should be considered absolute contraindications to laparoscopic echinococcectomy. It remains crucial to establish and refine optimal single-stage surgical approaches for managing multiple and complicated ECs of the liver, particularly when accompanied by involvement of other abdominal organs.

**Objective.** The study aimed to explore the feasibility of expanding indications for laparoscopic echinococcectomy in pediatric patients and to improve the outcomes of surgical treatment for complicated liver echinococcosis in children.

**Materials and Methods.** Between 2009 and 2023, laparoscopic echinococcectomy for complicated echinococcal liver disease (ELD) was performed on 72 pediatric patients at the Republican Scientific and Practical Center of Minimally Invasive and Endoscopic Surgery of Childhood (RSPCMI-ESC). The cohort included 46 boys (63.9%) and 26 girls (36.1%), aged 6 to 18 years. Among them, 16 children (22.2%) had previously undergone surgical interventions for ELD.

Analysis of complications revealed that the most common issue was suppurated echinococcal cysts (ECs), occurring in 38 patients (52.8%). Other complications included rupture of ECs into the bile ducts in 14 cases (19.4%), perforation of cyst contents into the free abdominal cavity in 16 patients (22.2%), and calcification of ECs in 4 cases (5.6%).

Table 1

**Distribution of patients by types of complications of echinococcosis of the liver (n=72)**

Type of complication	Number	
	abs.	%
Calcification	4	5,6
Suppuration	38	52,8
Rupture of EC into the bile ducts	14	19,4
Rupture of EC into the abdominal cavity	16	22,2
<b>Total</b>	<b>72</b>	<b>100</b>

Localization analysis revealed that the right lobe of the liver was affected in 53 patients (73.6%), with 41 children (56.9%) presenting subdiaphragmatic cysts. Isolated left lobe involvement was observed in 13 patients (18.1%), and multiple liver echinococcosis was detected in 24 cases (33.3%).

Among the 72 patients, primary echinococcosis accounted for 74% (69.1%), recurrent cases for 11% (15.2%), and residual cases for 5% (6.9%). Solitary ECs were identified in 53 patients (73.6%), while

19 patients (26.4%) had multiple lesions. Of those with multiple cysts, 13 (18.1%) had two cysts, and 11 (15.3%) had three or more.

The diagnostic approach combined clinical and laboratory assessments with imaging techniques, including liver and abdominal ultrasound, computed tomography (CT), chest X-rays, magnetic resonance imaging (MRI), and videolaparoscopy. This comprehensive evaluation allowed for precise identification of cyst characteristics, including their segmental location, size, number, and complications such as suppuration, biliary communication, or rupture into the biliary system. The detailed information enabled tailored planning for surgical interventions.

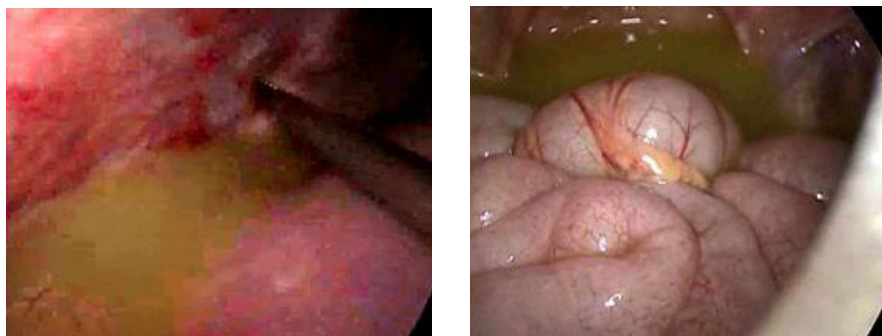**Results and Discussion.** Suppuration of parasitic cyst contents is the most frequent complication of liver echinococcosis. Among our cohort, 38 patients (52.8%) were admitted with suppurated echinococcal cysts (ECs) accompanied by pronounced clinical signs of purulent intoxication. Pain syndrome was the earliest and most consistent symptom. In cases involving the left lobe (n=6, 15.7%), pain was localized in the epigastric region. Cysts on the anterior or inferior surfaces of the right lobe caused pain in the right hypochondrium, while echinococcosis affecting the posterior-upper liver segments (VII–VIII) often presented as pain in the right side of the chest.

Abdominal asymmetry was observed in 14 patients (19.4%), primarily due to significant enlargement of the right abdominal region from long-growing cysts. In 11 patients (15.3%) with tense ECs, palpation of the epigastric region or right hypochondrium revealed hepatomegaly or a tumor-like structure with a smooth surface. General symptoms such as weakness, malaise, and sweating were present in 57 patients (79.2%). Dyspeptic manifestations were seen in 22 (30.1%), fever in 45 (62.5%), and urticaria in 9 (12.5%).

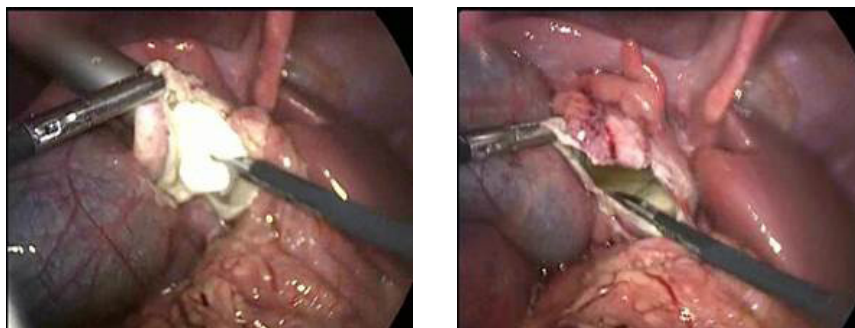
Cyst perforation into the abdominal cavity occurred in 16 patients (22.2%) and presented with anaphylaxis and peritonitis. Patients were admitted to the hospital approximately  $6.5 \pm 3.5$  hours after the first signs of peritonitis. In six cases (8.3%), abdominal trauma triggered the onset of peritonitis. Clinical examination revealed severe general condition, peritoneal signs, and urticaria with polymorphic rashes on the face, trunk, and limbs. Laboratory tests showed neutrophilic leukocytosis at  $17.6 \pm 0.6 \times 10^9/L$  and eosinophilia at  $9.2 \pm 0.8\%$ . Ultrasound identified free abdominal fluid and revealed the underlying cause—cystic formations in the liver. Preoperative management focused on correcting homeostasis and included detoxification, desensitization, and anti-shock therapy.

Rupture of ECs into the bile ducts was documented in 14 patients (19.4%). Clinical manifestations were influenced by the diameter of the affected duct and the size of the fistula. Symptoms included pain, severe toxicosis, and heightened sensitization due to absorption of parasitic fluid, along with signs of cholangitis. Notably, we did not observe mechanical jaundice from obstruction caused by daughter cysts or fragments of the chitinous membrane. Calcified liver ECs were detected in 4 patients (5.6%), diagnosed through ultrasound, plain abdominal radiography, and CT imaging.

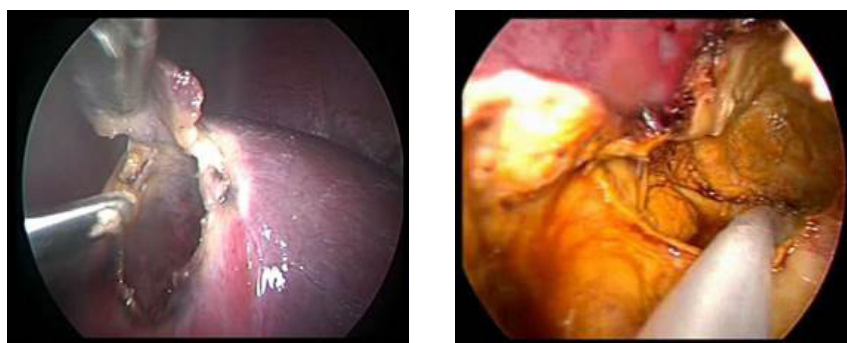
Surgical treatment commenced with diagnostic laparoscopy in all cases. Following the introduction of laparoscopic optics, the abdominal cavity was examined to determine the extent of the disease and establish intraoperative strategy. ECs appeared as round, whitish formations protruding from the liver surface. During diagnostic laparoscopy, the cysts' location was identified, and additional working trocars were placed depending on their positioning. Instrumental palpation revealed that ECs were denser than liver tissue. Adhesions between the Glisson capsule and diaphragm, as well as between the cyst's fibrous membrane and the greater omentum, served as indirect signs of cyst localization.



**Figures 1–2.** Intraoperative visualization of purulent effusion in the abdominal cavity resulting from the perforation of a liver echinococcal cyst. Fragments of the chitinous membrane are also visible



**Figures 3–4.** Vacuum extraction of residual fluid and chitinous membrane fragments from the opened echinococcal cyst



**Figures 5–6.** Drainage of the residual cavity (RC) of the liver and abdominal cavity after antiparasitic treatment

Using monopolar electrocoagulation, some adhesions were dissected to improve the surgical view and expand access to the cysts for manipulation. Suppurated ECs were associated with cloudy effusions in the abdominal cavity. In cases of cyst perforation, fragments of the chitinous membrane were visible (Figs. 1–2). After introducing an additional trocar, the abdominal cavity was re-evaluated to assess the extent of the disease. Effusions and membrane fragments were evacuated using electric suction, and the abdominal cavity was sanitized with antiseptic solutions (e.g., ozonated water, decosan) until clear fluid was achieved.

After bipolar coagulation, the fibrous membrane of the opened cyst was widely dissected. Residual fluid and remnants of the chitinous membrane were aspirated using vacuum extraction (Figs. 3–4). The inner surface of the fibrous capsule underwent antiparasitic treatment with an 80–100% glycerin solution, 3% hydrogen peroxide, and 96% alcohol. Finally, the residual cavity (RC) of the liver and the abdominal cavity were drained (Figs. 5–6).

In 11 (15.3%) patients, additional uncomplicated echinococcal cysts (EC) were identified and removed laparoscopically. During surgery, small cholecysto-biliary fistulas were detected in 37 (51.4%) patients and were managed endosurgically through suturing or coagulation with a bipolar coagulator.

Elimination of the residual cavity (RC) of the liver is a crucial final stage in surgical treatment of hepatic echinococcosis. Laparoscopic echinococcectomy, involving excision of the fibrous capsule within liver tissue and drainage of the RC (without suturing or capitonnage), was performed in 49 (68.1%) patients. These cases primarily involved suppurated large and giant ECs with dense, rigid, and occasionally calcified walls.

In 11 (15.3%) patients, small- and medium-sized additional ECs located in segments IV–V–VI of the right lobe and segments II–III of the left lobe were identified. For these cysts, the RC was sutured from the bottom using extracorporeal knots.

In 12 (12.7%) patients with large ECs near the porta hepatis, the visceral surface, and subdiaphragmatic segments VII–VIII, an abdominalization technique of the RC with omentopexy was applied.

In cases where there was insufficient omentum majus for omentopexy (due to atrophy), after excision of the fibrous capsule, the residual cavity (RC) was drained using a silicone tube with side holes (Table 2).

Table 2

Laparoscopic interventions to eliminate the RC of EC

Laparoscopic operations	Number	
	abs.	%
Laparoscopic echinococcectomy with suturing of the RC from the inside	11	15,3
Laparoscopic echinococcectomy with partial excision of the fibrous capsule, tamponade of the RC with omentum	12	12,7
Laparoscopic echinococcectomy with excision of the fibrous capsule without suturing of the RC	49	68,1
Conversion for multiple liver cysts	13	18,1

Laparoscopic visualization in cases of multiple and combined EC of the abdominal organs, particularly with intraparenchymal localization or cysts on the diaphragmatic surface of the liver (segments VII-VIII), presents certain challenges. In these instances, intraoperative ultrasound was utilized when ECs were suspected but not visible during laparoscopy. This technique helped clarify the topography of the focal formations, delineating sectoral and segmental boundaries of the liver.

During the course of our laparoscopic echinococcectomy procedures, we encountered 13 (18.1%) cases requiring conversion from laparoscopic to open surgery. The reason for this conversion was the presence of multiple, deeply located liver cysts in segments that could not be accessed with laparoscopic tools. These cases involved complete intrahepatic cysts in positions technically inaccessible for laparoscopy, necessitating a shift in surgical approach.

Laparoscopic echinococcectomy has proven to be an effective technique in addressing complicated cases of hepatic echinococcosis, particularly those involving cyst suppuration and rupture into the abdominal cavity. Despite the challenges encountered, the outcomes from this surgical approach have been promising, offering advantages in terms of reduced invasiveness and quicker recovery times.

**Postoperative Care and Recovery.**

Post-surgery, our management strategy included the use of non-narcotic analgesics for pain relief, typically administered during the first 24 hours. Most patients were able to begin mobilizing within the first 1–2 days after surgery, a key aspect of promoting recovery. Notably, 49 (68.1%) of the pediatric patients were discharged within 7 to 10 days following the operation, showcasing the relatively swift recovery period facilitated by laparoscopic intervention.

While laparoscopic echinococcectomy is technically less traumatic than open surgery, it does present challenges in some cases. In 13 (18.1%) children, multiple liver lesions or extrahepatic cysts, found in the spleen, diaphragm, abdominal cavity, and small pelvis, caused significant difficulties. These complications arose because the laparoscopic tools could not reliably determine the exact depth or location of deeply embedded cysts. In these cases, well-visualized cysts were excised laparoscopically first, and then, once the laparoscopic approach was found to be insufficient, a conversion to an open method was necessary. During the open procedure, intraoperative ultrasound was used to accurately locate any remaining cysts, ensuring complete excision of the parasite. Fortunately, no intraoperative complications proved life-threatening, and the overall safety of the procedure remained intact.

**Postoperative Course and Outcomes.**

Patients who underwent laparoscopic echinococcectomy for complicated liver cysts generally experienced a favorable postoperative course. The mean time for body temperature to normalize was  $2.5 \pm 0.15$  days, which suggests effective management of infection and inflammation. One of the primary benefits of laparoscopic surgery is its minimal invasiveness, which significantly reduces pain and shortens recovery time. Pain was typically controlled within  $1.8 \pm 0.2$  days, which is markedly quicker than that experienced in traditional open procedures.

Most patients were mobilized by the  $2.5 \pm 0.17$ -day mark, contributing to faster rehabilitation and reduced risk of postoperative complications such as deep vein thrombosis. Drains were typically removed on day  $5.6 \pm 0.2$  after surgery, further reducing the duration of inpatient care. Once discharged, patients continued treatment with albendazole, 12 mg/kg per day, for 28 days, followed by a 30-day break before commencing the second course. This regimen was designed to ensure eradication of any residual parasitic activity.

### **Long-Term Monitoring and Follow-Up.**

Follow-up examinations were conducted quarterly for one year to monitor the progression of recovery and the state of the residual cavities. These control checks, primarily using ultrasound, provided invaluable insights into the effectiveness of the surgery and the recovery process. The findings revealed that one year post-surgery, 53 (73.6%) of the patients had no pathological formations in the liver, which is a highly encouraging outcome for this cohort.

In 14 (19.6%) cases, we observed small, laminar, or irregular residual cavities filled with tissue debris, but these were generally not associated with any significant complications. In 5 (6.9%) patients, larger residual cavities of more than 7-8 cm were noted, which required percutaneous drainage to facilitate further healing. These cavities were successfully managed, and the patients recovered without the need for additional surgical intervention.

### **Challenges and Future Directions.**

While the laparoscopic approach to echinococcectomy has shown promising results, it is not without its limitations. As discussed, in cases of multiple lesions or cysts located in technically difficult areas of the liver, conversion to open surgery may be necessary to ensure complete removal of all cysts. This highlights the need for continued improvement in laparoscopic techniques and equipment, as well as further research to explore ways to overcome these challenges.

Moreover, the long-term monitoring of patients after surgery is essential in ensuring that any recurrence of echinococcosis is detected early. The regular follow-up using imaging techniques, such as ultrasound, remains a cornerstone of postoperative care. Given the potential for residual cysts or other complications, careful monitoring of patients for up to a year is crucial in achieving the best possible outcomes.

In conclusion, laparoscopic echinococcectomy offers significant advantages for pediatric patients with complicated liver echinococcosis, providing a minimally invasive option with a relatively quick recovery time. Despite some technical challenges, particularly in cases of deeply located cysts or multiple lesions, this approach remains highly effective in managing the disease. The combination of careful surgical technique, post-operative monitoring, and the use of antiparasitic drugs ensures that the majority of patients experience successful outcomes. Future advancements in laparoscopic technology and surgical techniques may further enhance the efficacy and safety of this approach in treating complicated cases of hepatic echinococcosis.

### **Conclusions.**

#### **1. Initial Surgical Approach for Complicated Cases**

In cases of echinococcal disease complicated by suppuration and cyst perforation, we strongly recommend commencing the surgical procedure with diagnostic laparoscopy. This approach allows for an immediate assessment of the cyst's condition and surrounding anatomical structures, which aids in determining the most appropriate intraoperative strategy. The ability to visualize the cyst's location and complications ensures that subsequent actions, such as cyst evacuation or drainage, can be tailored effectively to prevent further complications.

#### **2. Feasibility and Benefits of Laparoscopic Echinococcectomy**

For the vast majority of pediatric patients with multiple and complicated hepatic echinococcosis, laparoscopic echinococcectomy proves to be a viable and effective treatment option. This minimally invasive technique significantly reduces the extent of surgical aggression compared to traditional open surgery, leading to less trauma, quicker recovery times, and a smoother postoperative course. The reduced need for incisions and tissue manipulation enhances patient comfort and accelerates the healing process, contributing to improved overall outcomes in the postoperative phase.

#### **3. Considerations for Perforation and Peritonitis**

Complicated cases of echinococcosis involving cyst perforation and peritonitis, particularly those associated with extensive liver disease (ELD) in children, represent a relative contraindication to performing laparoscopic echinococcectomy. The presence of widespread peritoneal contamination and inflammation can increase the risk of complications during laparoscopic surgery, potentially compromising the safety and effectiveness of the procedure. In such cases, careful consideration should be given to the patient's clinical condition before opting for laparoscopic intervention.

#### **4. Laparoscopic Approach as the Preferred Method**

Laparoscopic echinococcectomy should be considered the method of choice for the treatment of liver echinococcosis in pediatric patients, particularly in non-complicated cases. This approach not only offers substantial clinical advantages, such as reduced postoperative pain and faster recovery times but also provides significant economic benefits. By shortening both inpatient and outpa-

tient treatment durations, laparoscopic surgery reduces healthcare costs and optimizes the overall management of patients. Furthermore, the minimally invasive nature of laparoscopic techniques decreases the risk of long-term complications, thereby enhancing the patient's quality of life.

### Литература/References

1. Alperovich B.I., Sorokin R.V., Tolkaeva M.V., Budkov S.R. Surgical treatment of recurrent liver echinococcosis. *Annals of surgical hepatology*. 2006; 11 (1): 7-10.
2. Madaliev I.N., Boymurodov O.S., Salimov D.S. System of antiparasitic treatment in the complex of surgical rehabilitation of patients with liver echinococcosis. In the book: *Problems of gastroenterology*. Dushanbe–Moscow: 2005; 3-4: 161-3.
3. Nazarov Sh.K. Surgical treatment of suppurating echinococcosis of the liver, which has broken into the bile ducts. In the book: *Current problems of modern medicine: scientific and practical materials. conferences*. M.: 2005: 37.
4. Vollmer C. et al. Reduced blood loss using hydro-jet technique for hepatic parenchymal dissection. *J. Gastrointest. Surg.* 2003; 7 (2): 283.
5. Bykova A.M. Helminths of wild carnivores in the Omsk region. In the book: *Current issues of theoretical and practical parasitology. Materials of the scientific and practical conference*. Omsk; 2004: 33-8.
6. Saritas U. Effectiveness of endoscopic treatment modalities in complex hepatic hydatid disease after surgical intervention. *Endoscopy*. 2001; 33(10): 856–63.
7. Mirkhodzhaev I.A. and others. Surgical treatment of recurrent forms of liver echinococcosis. *Annals of surgical hepatology*. 2008; 13(3): 63.
8. Nazyrov F.G., Akilov Kh.A., A.I. Ikramov, N.M. Juraeva, F.A. Ilkhamov, Agzamkhodzhaev S.S. Radiation research methods in the diagnosis and treatment of purulent complications of liver echinococcosis // *Annals of Surgical Hepatology*. 2001; 6 (1): 47-50.
9. Ilkhamov F. A. Possibilities of endovisual technology for liver echinococcosis. *Annals of surgical hepatology*. 2004; 9 (2): 85.
10. Medzhidov R.T. and others. Surgical treatment of abdominal echinococcosis. *Annals of surgical hepatology*. 2007; 2:43-8.
11. Kharnas S.S., Lotov A.N., Musaev G.Kh. Ultrasound semiotics and classification of liver echinococcosis. *Medical imaging*. 2006; 4: 46-51.
12. Baskaran V., Patneik P.K. Feasibility and safety of laparoscopic management of hydatid disease of the liver. *Soc. Caparoendosc. Surge*. 2004; 359-63.